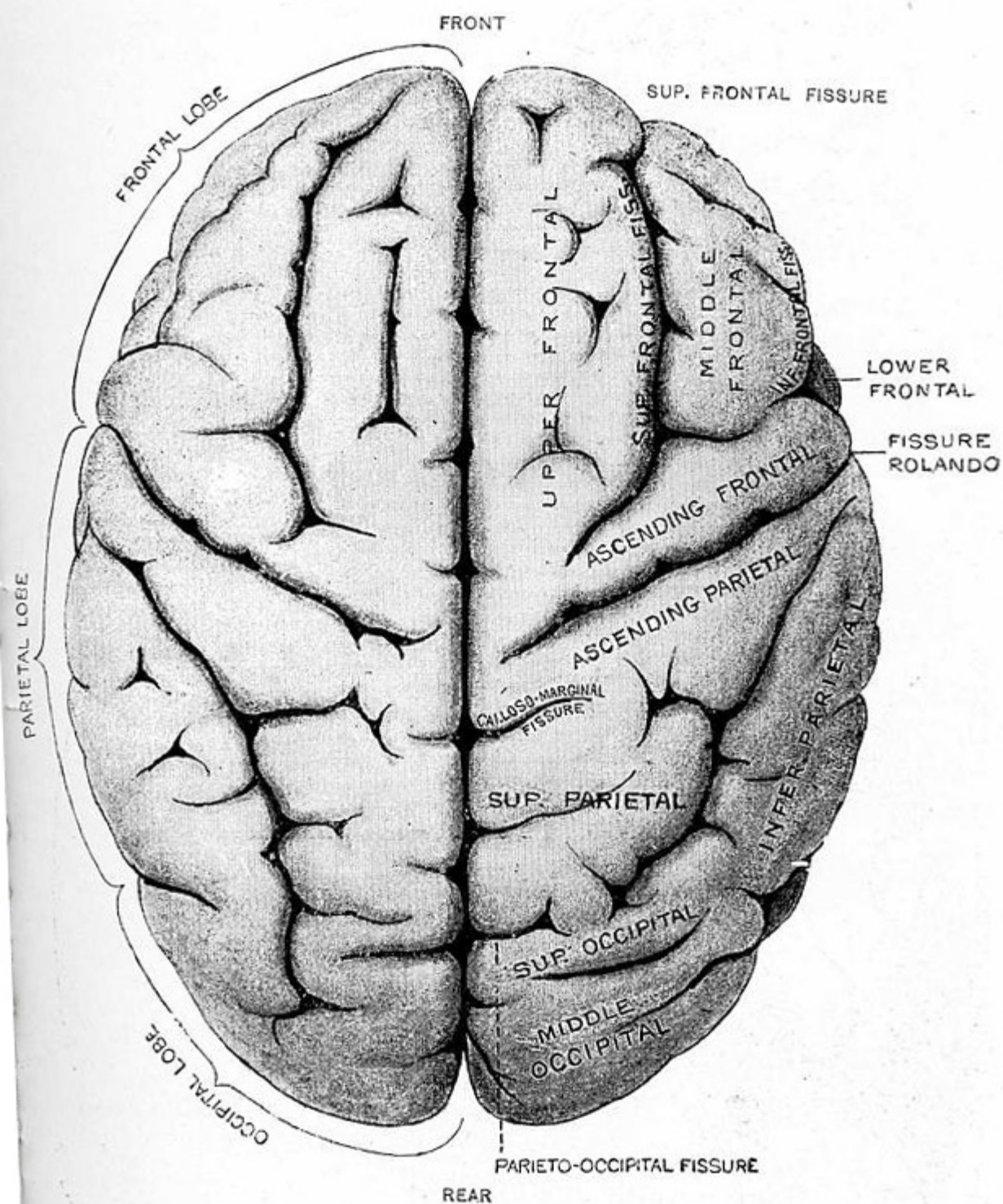


Fig. VI.—Upper surface of Brain, arachnoid membrane being removed. (Gray.)



This illustration shows the chief convolutions and fissures of the cerebrum from above. The two hemispheres are divided by the great longitudinal or median fissure.

(See Text, pp. 45, 567—570).