



APPENDICULAR SKELETON




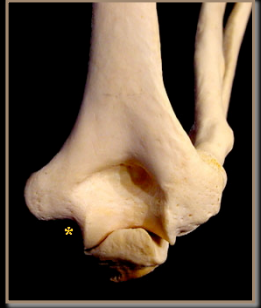


Humerus	Patella
Radius	Tibia
Ulna	Fibula
Hands	Talus
Femur	Calcaneus

HUMERUS

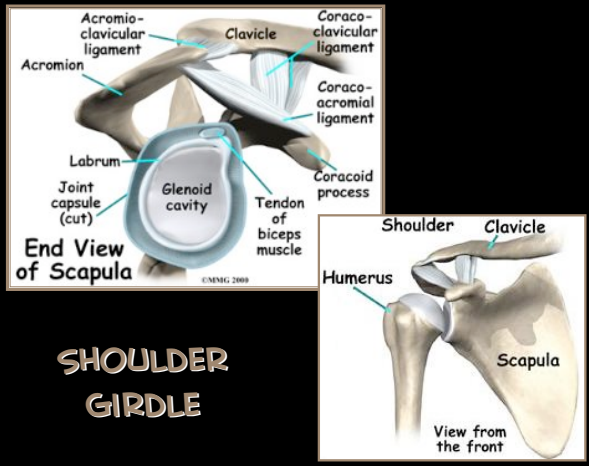


- Head
- Greater Tubercle
- Intertubercular Groove
- Lesser Tubercle
- Deltoid Tuberosity
- Lateral Epicondyle
- Medial Epicondyle
- Capitulum
- Trochlea
- Olecranon Fossa




- Intertubercular Groove
- Greater Tubercle
- Lesser Tubercle
- Capitulum
- Trochlea
- Head
- Lateral Epicondyle
- Medial Epicondyle
- Olecranon Fossa

SHOULDER GIRDLE


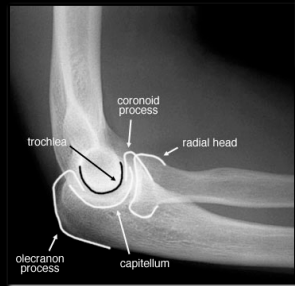



- Acromion
- Acromioclavicular ligament
- Clavicle
- Coracoclavicular ligament
- Coracoacromial ligament
- Coracoid process
- Labrum
- Joint capsule (cut)
- Glenoid cavity
- Tendon of biceps muscle
- Shoulder
- Clavicle
- Humerus
- Scapula

MUSCLE ATTACHMENTS

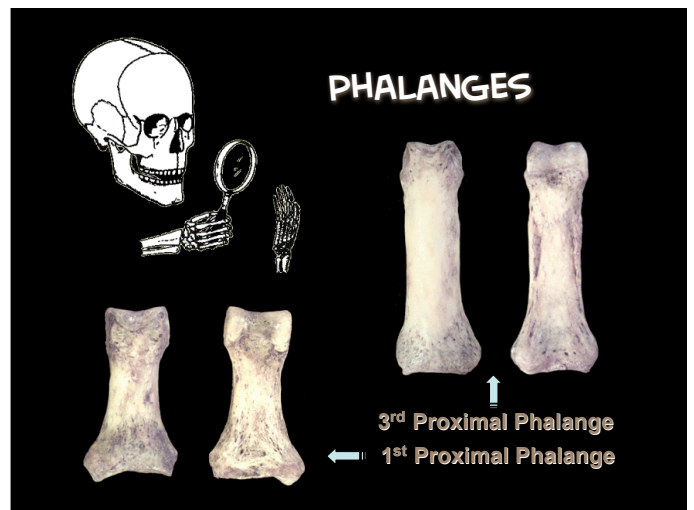
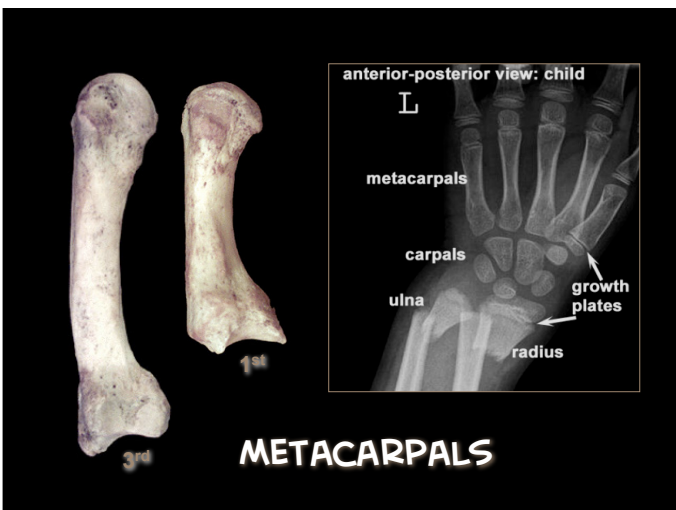
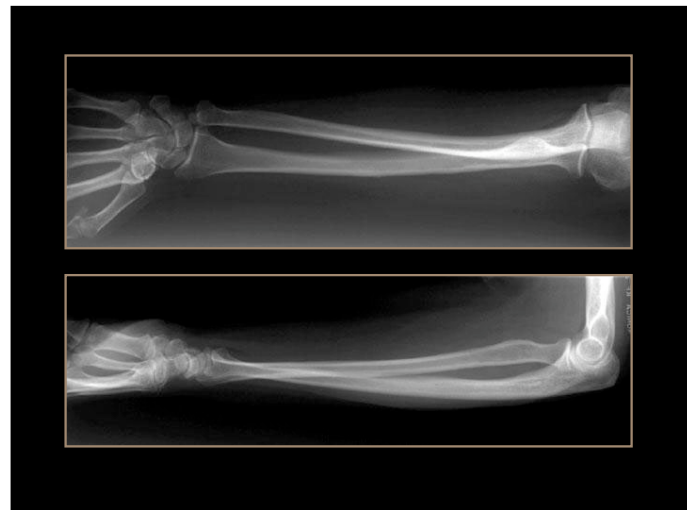
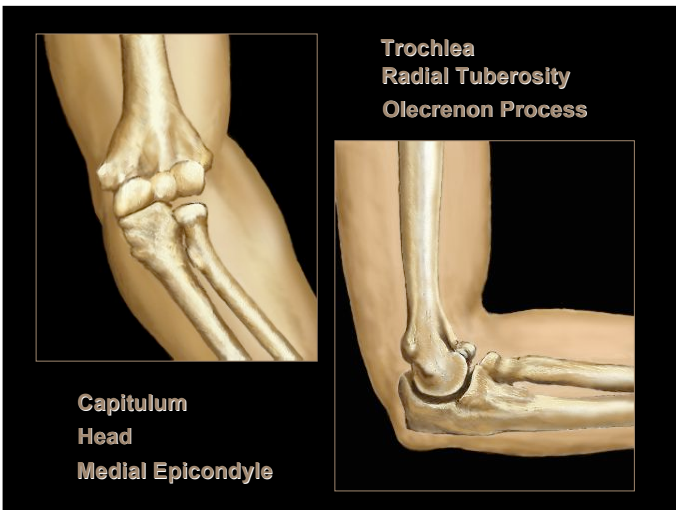
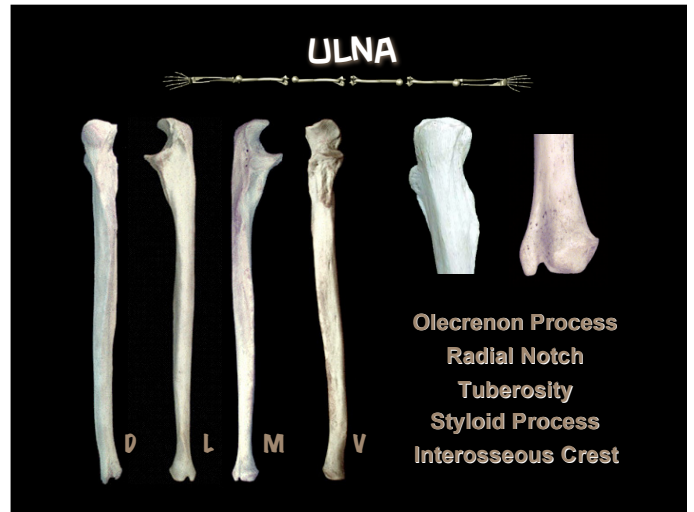
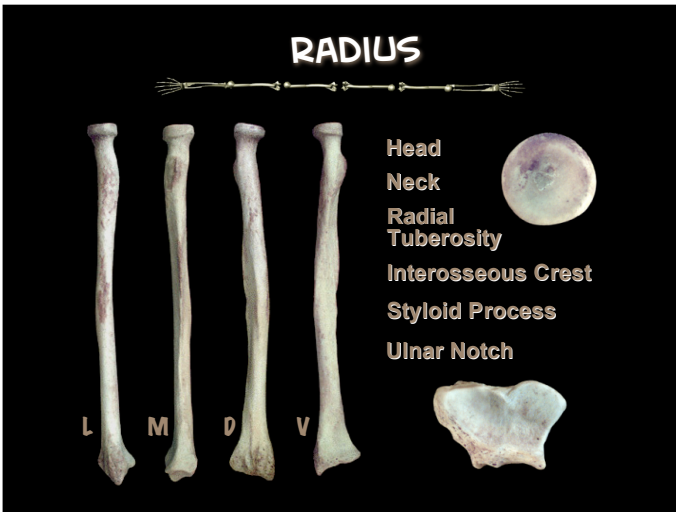
Biceps & Triceps **Deltoid**

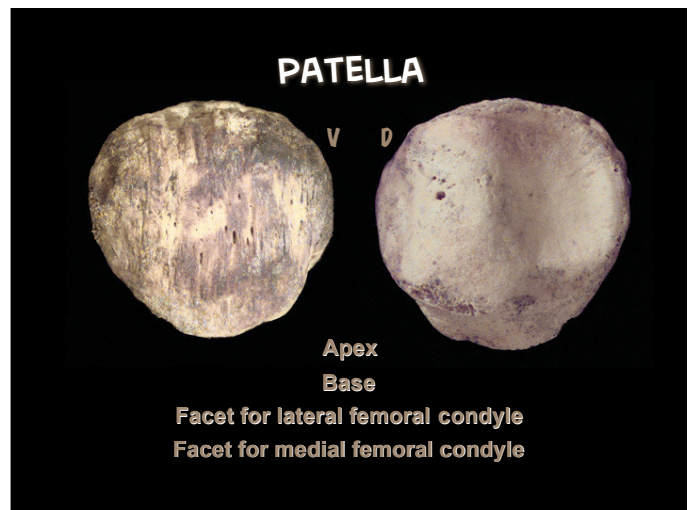
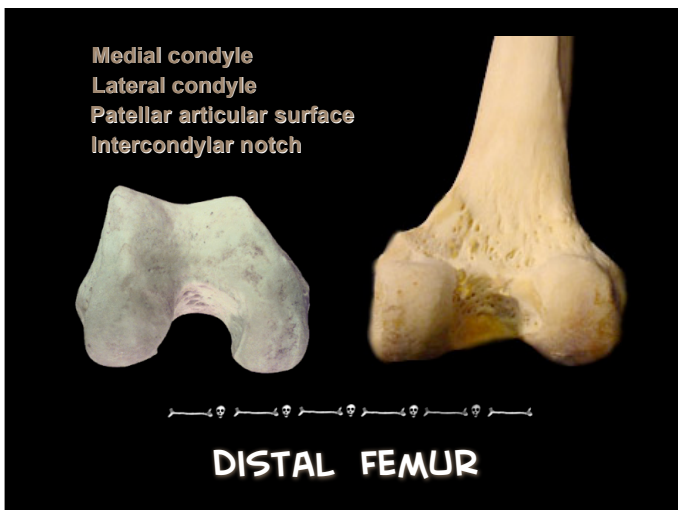
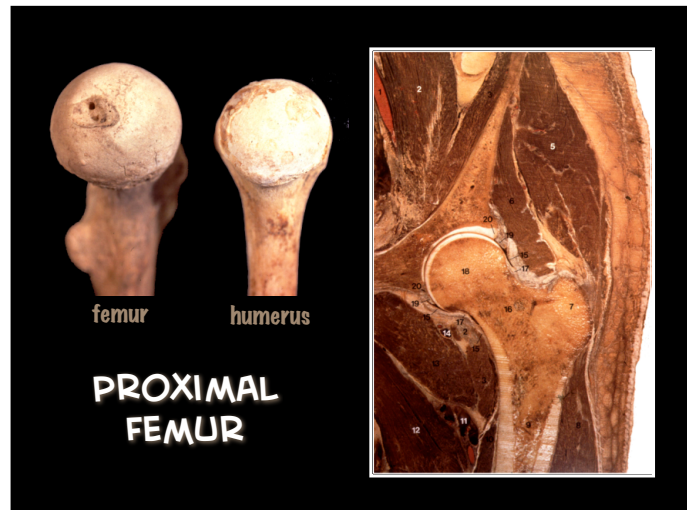
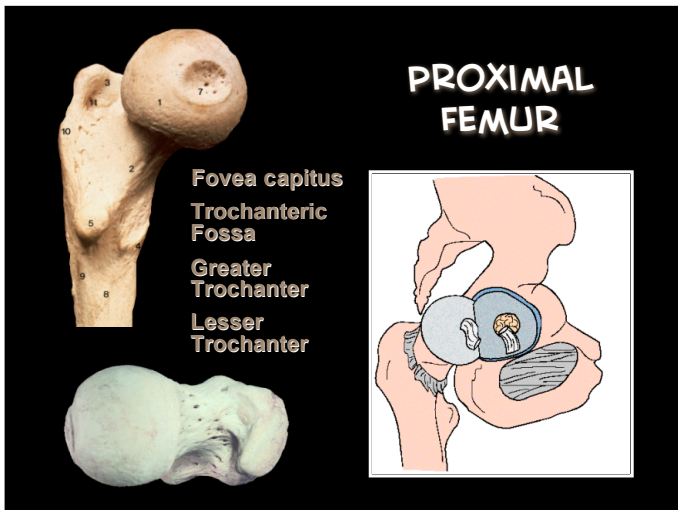
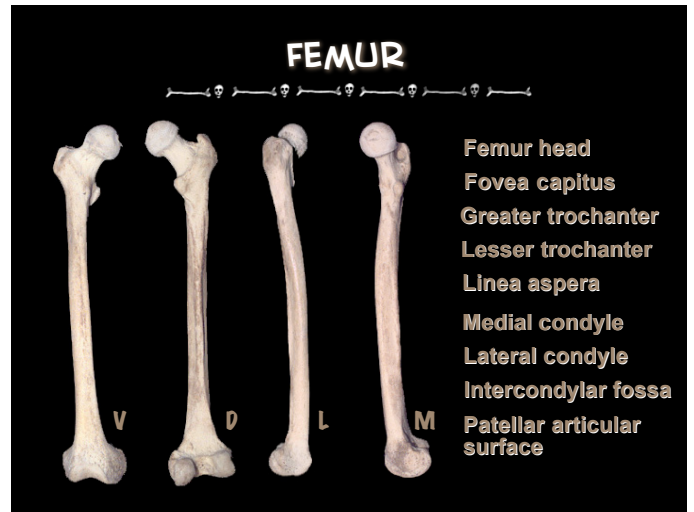
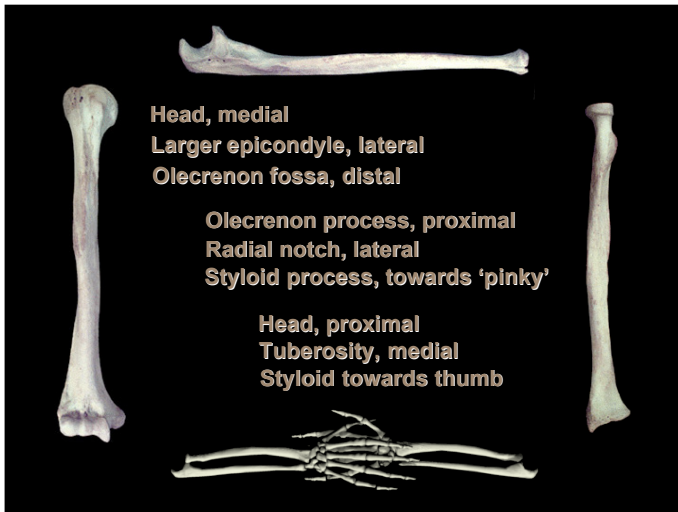




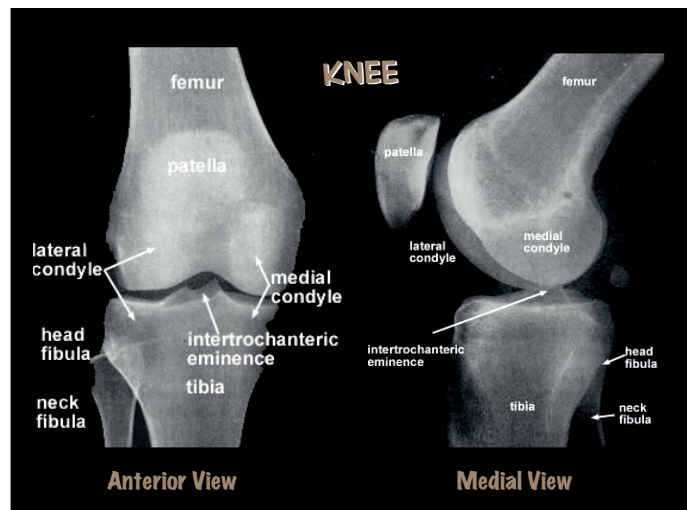
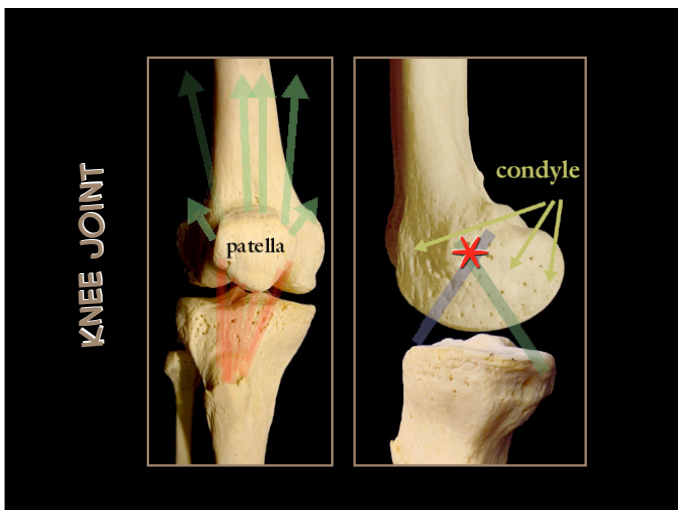
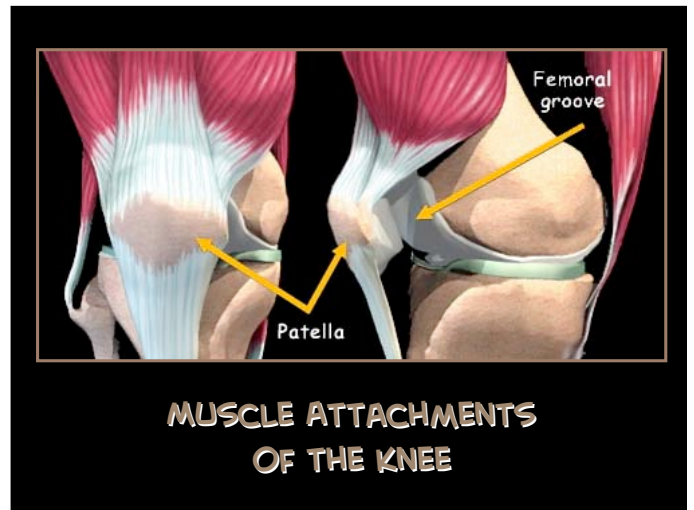
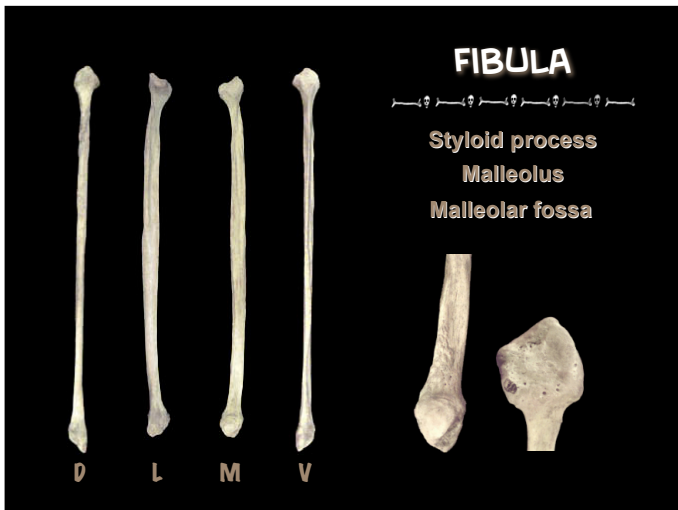
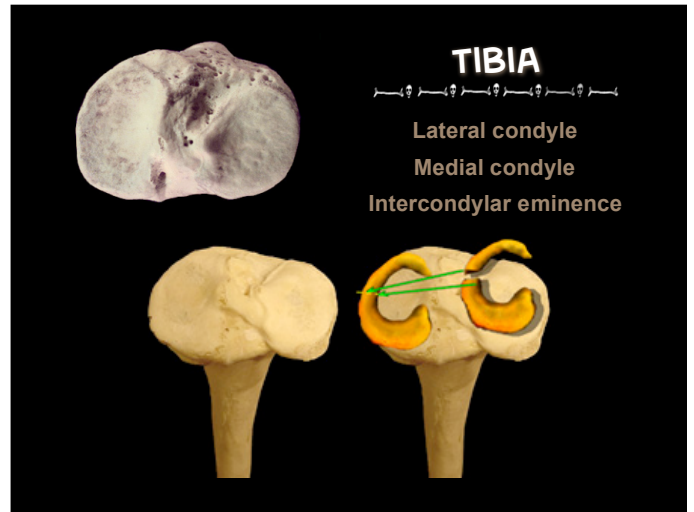
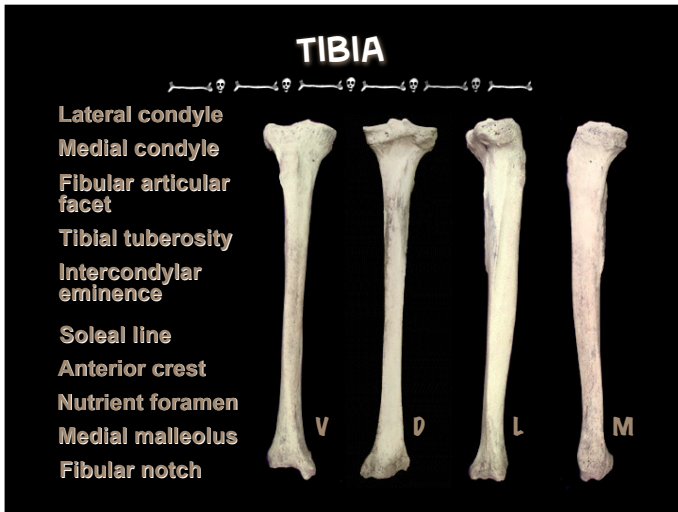
Proximal End →

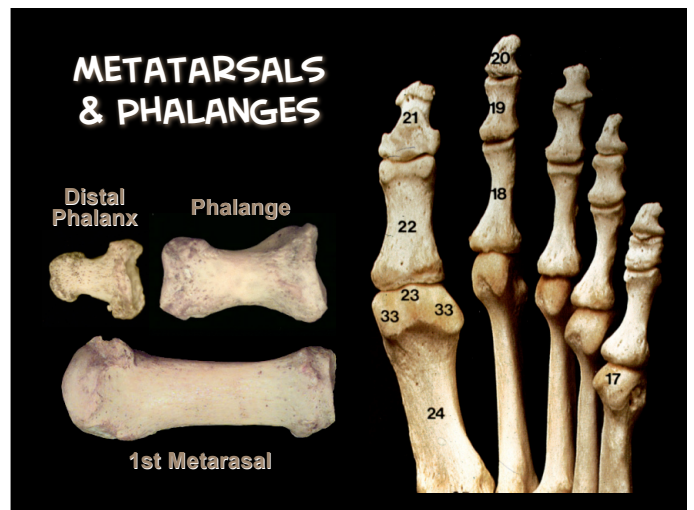
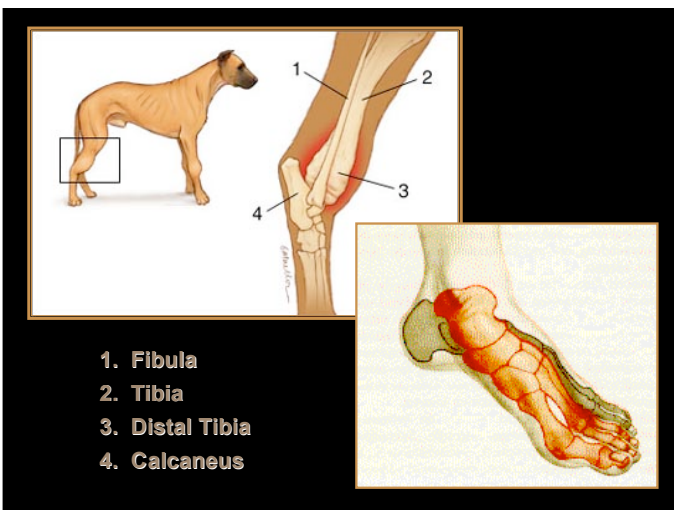
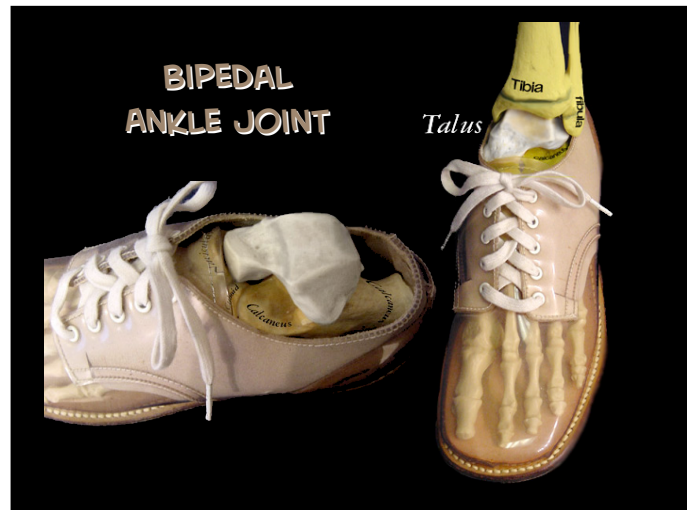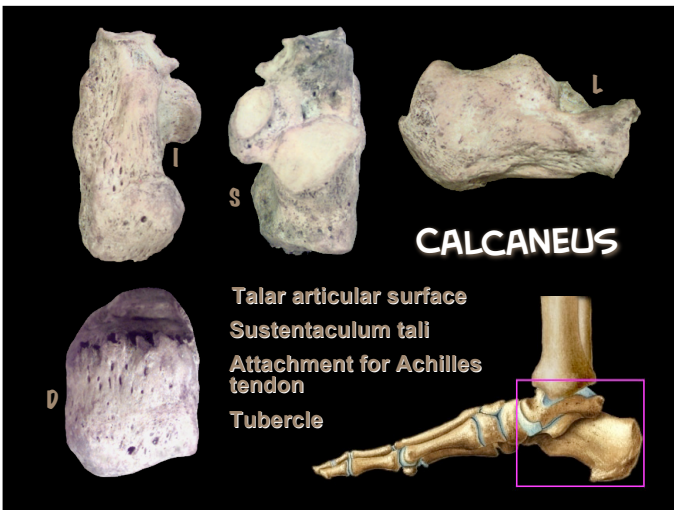
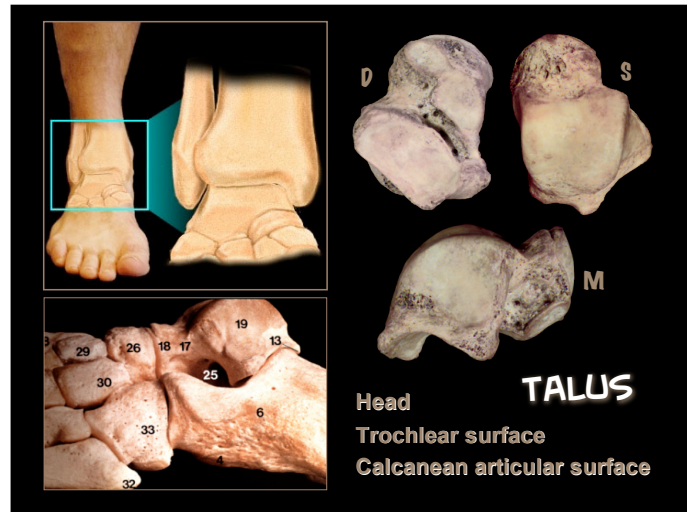
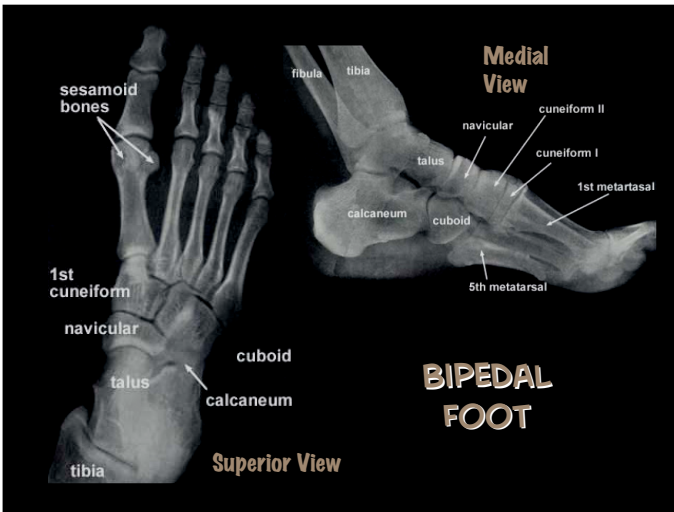
Distal End ↓

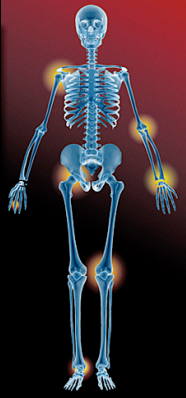- trochlea
- olecranon process
- coronoid process
- radial head
- capitulum



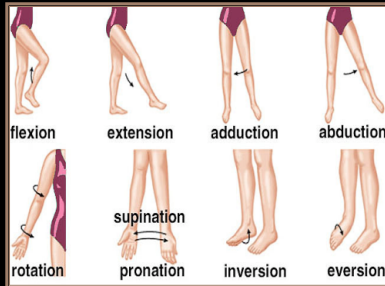








APPENDICULAR JOINT MOVEMENTS



FOOT TENDONS/LIGAMENTS

